

The Role of Laparoscopy in the Diagnosis and Management of Pediatric Trauma

Trauma Rounds
January 24, 2011

Dr. Andrea Lo

Fellow, Pediatric General Surgery

McGill University, Montreal Children's Hospital



NO CONFLICTS OF INTEREST



Outline/Objectives

- Rationale for Use of Laparoscopy
- Summary of Literature
- Review of Large Series (2)
- Conduct of Laparoscopy
- Injuries Amenable to Laparoscopic Management
- Indications for Conversion to Laparotomy
- Thoracoscopy
- Our Experience
- Conclusions and Proposed Algorithms



Rationale for Use of Laparoscopy

- improved **diagnostic accuracy** compared to
 - FAST: poor specificity
 - DPL: poor specificity, invasive, not informative for retroperitoneal injuries
 - CT: hollow viscus injuries difficult to identify
- reduction of **nontherapeutic laparotomy** rates
- reduction of short and long-term **morbidity**
 - ↓ ICU stay, ↓ overall LOS
 - ↓ risk future adhesive bowel obstruction



Summary of Literature

- The use of minimal access surgery in pediatric trauma: a preliminary report
J Laparoendoscopic Surg 1995;5:295-301
8 patients
- The use of laparoscopy in management of seat belt trauma in children
J Laparoendoscopic Surg 1996;6:S45-9
4 patients
- Diagnostic laparoscopy for dog bite wounds to the abdomen
J Laparoendoscopic Surg 1996;6:435-6
case report



Summary of Literature

- Laparoscopy in pediatric abdominal trauma
JLS 1997;1:349-51
case report diagnostic + therapeutic laparoscopy for jejunal perforation in MVC blunt trauma 4yo
- Laparoscopic diagnosis of blunt abdominal trauma in children
Pediatr Surg Int 1997;12:132-6
5 patients 3-13yo
- Laparoscopic evaluation of the traumatized spleen with blood salvage for autotransfusion
Am Surg 1997;63:478-80
case report 15yo blunt abd trauma with CT gr 3 splenic injury
- Laparoscopy in a case of pediatric blunt abdominal trauma
Surg Endosc 2002;16:358
case report diagnostic + therapeutic laparoscopy for gallbladder rupture in 7yo fell off bicycle



Summary of Literature

- Innovative minimally invasive pediatric surgery is of therapeutic value for splenic injury
J Pediatr Surg 2002;37:1146-50
19 patients
- A case of a traumatic abdominal wall hernia that could not be identified until exploratory laparoscopy was performed
Pediatr Surg Int 2005;21:54-7
case report diagnostic laparoscopy → open repair
- Laparoscopic repair of traumatic bowel injury in children
J Pediatr Surg 2006;41:1864-9
8 patients repaired laparoscopically + 6 patients repaired lap-assisted



Summary of Literature

- Management of traumatic complete pancreatic fracture in a child: case report and review of the literature
J Laparoendosc Adv Surg Tech A 2008;18:321-3
case report distal pancreatectomy
- Laparoscopic omentectomy for omental infarction after bicycle handlebar injury
J Laparoendosc Adv Surg Tech A 2008;18:327-9
case report
- Laparoscopic drainage of a post-traumatic intramural duodenal hematoma in a child
J Laparoendosc Adv Surg Tech A 2008;18:469-72
case report



Review of Large Series (1)

Diagnostic and therapeutic laparoscopy in pediatric abdominal trauma
J Pediatr Surg 2006;41:72-7

- retrospective review 2000-2004, Children's Hospital of Pittsburgh
- 7127 trauma admissions → 113 surgical explorations = 81 laparotomy + 32 laparoscopy
- 88% blunt trauma vs. 12% penetrating (GSW, stab, glass, tree branch, bicycle handlebar, pitchfork)



Review of Large Series (1)

Diagnostic and therapeutic laparoscopy in pediatric abdominal trauma
J Pediatr Surg 2006;41:72-7

- indications for laparoscopy: blunt or penetrating abd trauma + HD stable +
 - suspicious physical exam eg. abd wall contusion, peritonitis
 - labs eg. declining hematocrit
 - CT diagnostic or suspicious for hollow viscus injury eg. FA, enteral contrast extravasation, FF in absence of solid organ injury, thickened bowel loops, mesenteric infiltration
- patients who underwent laparoscopy had higher GCS, lower ISS → lower ICU days, lower overall LOS vs. laparotomy



Review of Large Series (1)

Diagnostic and therapeutic laparoscopy in pediatric abdominal trauma
J Pediatr Surg 2006;41:72-7

- neg laparoscopy in 9 (28%)
- pos laparoscopy in 23 (72%)
 - 3 nontherapeutic = nonexpanding mesenteric/retroperitoneal hematoma
 - 6 laparoscopic repair = 3 perforated hollow viscus + 2 mesenteric defects + 1 FB removal
 - 14 converted to open for repair = 10 perforated hollow viscus + 3 diaphragmatic rupture + 1 distal pancreatic injury



Review of Large Series (1)

Diagnostic and therapeutic laparoscopy in pediatric abdominal trauma
J Pediatr Surg 2006;41:72-7

- laparotomy avoided in 56%
 - no missed injuries
 - no technical complications
 - no deaths (vs. 6 laparotomy group)
- » laparoscopy in pediatric trauma is a safe method for the evaluation and treatment of selective blunt and penetrating abdominal injuries in hemodynamically stable patients ... reduces the morbidity of a negative laparotomy



Review of Large Series (2)

Use of laparoscopy in the management of pediatric abdominal trauma
J Trauma 2010;69:761-4

- retrospective review 1997-2009, Children's Hospital of Alabama
- 4836 trauma admissions → 92 surgical explorations = 71 laparotomy + 21 laparoscopy
 - 19 acute laparoscopies + 2 delayed laparoscopies



Review of Large Series (2)

Use of laparoscopy in the management of pediatric abdominal trauma
J Trauma 2010;69:761-4

- **successful diagnostic laparoscopy** = attained correct diagnosis = 19 (90.5%)
- **successful therapeutic laparoscopy** = able to repair injury laparoscopically = 5 (100%)
- **avoidance of laparotomy** = correct diagnosis attained laparoscopically + able to repair injury laparoscopically = 13 (62%)



Review of Large Series (2)

Use of laparoscopy in the management of pediatric abdominal trauma
J Trauma 2010;69:761-4

- pos laparoscopy in 19 (90.5%)
 - 7 nontherapeutic = liver laceration, SB/colonic contusion/hematoma, excluded peritoneal violation in 5 penetrating injuries
 - 5 laparoscopic repair = FB removal (GSW); reduction of omentum + repair abd wall (stab); repair 2 enterotomies + colostomy (GSW); repair SB perforation (seat belt blunt injury); FB removal + cholecystectomy (GSW)
 - 7 converted to open for repair = retrieval FB, perforated hollow viscus injuries (duodenal, multiple), mesenteric laceration, 2 delayed presentation with dense adhesions



Review of Large Series (2)

Use of laparoscopy in the management of pediatric abdominal trauma
J Trauma 2010;69:761-4

- laparotomy avoided in 62%
 - no deaths (vs. 6 laparotomy group)
- » diagnostic and therapeutic laparoscopy is safe in the management of the hemodynamically stable pediatric patient with acute blunt abd trauma with free fluid in the absence of solid organ injury, or persistent abd pain, tenderness, or tachycardia concerning a SB injury
- » laparoscopy is also useful in the diagnosis of penetrating abd trauma by identifying the possibility of peritoneal violation



Conduct of Laparoscopy

- matched pRBCs available
- be prepared for rapid conversion to open
- GA/ETT
- NG/OG
- Foley



Conduct of Laparoscopy

- 5mm umbilical trocar
- 2+ 3-5mm trocars → L flank, suprapubic
- 4 quadrant evaluation for blood, bile, urine, fecal contamination
- liver, spleen
- diaphragm, peritoneal surfaces
- SB + mesentery
- stomach, duodenum, colon
- explore lesser sac + pancreas as directed by CT



Injuries Amenable to Laparoscopic Repair

- duodenal lacerations, decompression of hematomas
- SB perforations (lap, lap-assisted)
- colonic perforations without significant contamination
- stoma formation for colonic + intraperitoneal rectal injuries
- splenic hemostasis, splenorrhaphy, splenectomy
- liver hemostasis
- distal pancreatectomy
- cholecystectomy



Indications for Conversion to Laparotomy

- acute hemodynamic deterioration
- dense adhesions
- gross intestinal distention
- bleeding that cannot be controlled laparoscopically
- injuries not amenable to laparoscopic repair



Thoracoscopy

- removal of FB under direct vision
- evaluation +/- repair of diaphragm



Our Experience: SP

8 yo M, previously healthy

- blunt abd trauma ~28h prior to presentation: fell on scooter handlebar
- Ø LOC, Ø HI
- ++ vomiting last pm, Ø blood/bile
- ++ periumbilical pain, ↑ today

O/E

- looks unwell, though afeb VSS RA
- ABD initially soft, tender R → guarding



Our Experience: SP

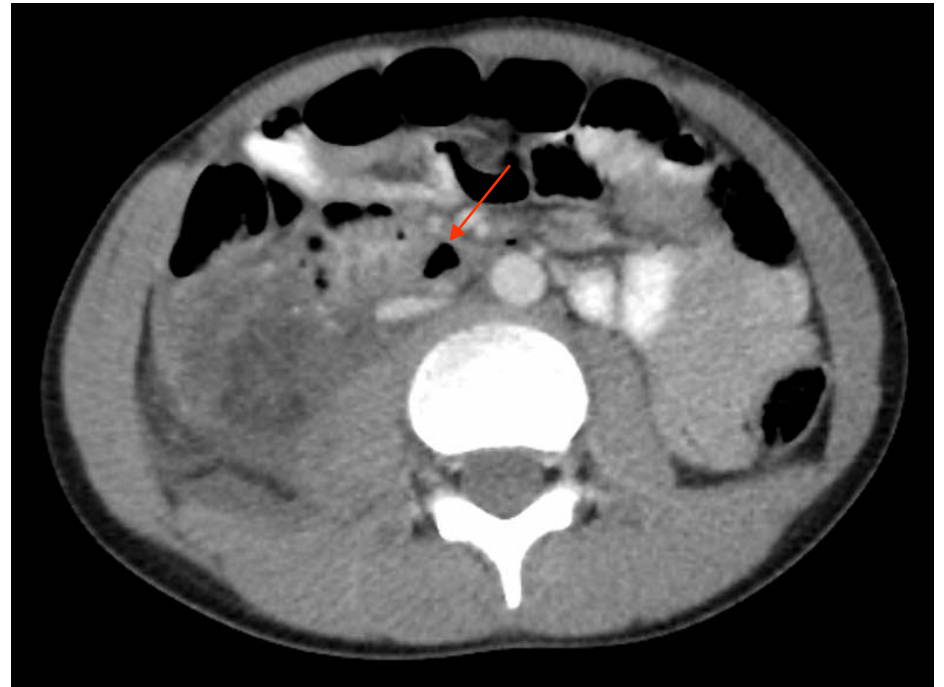
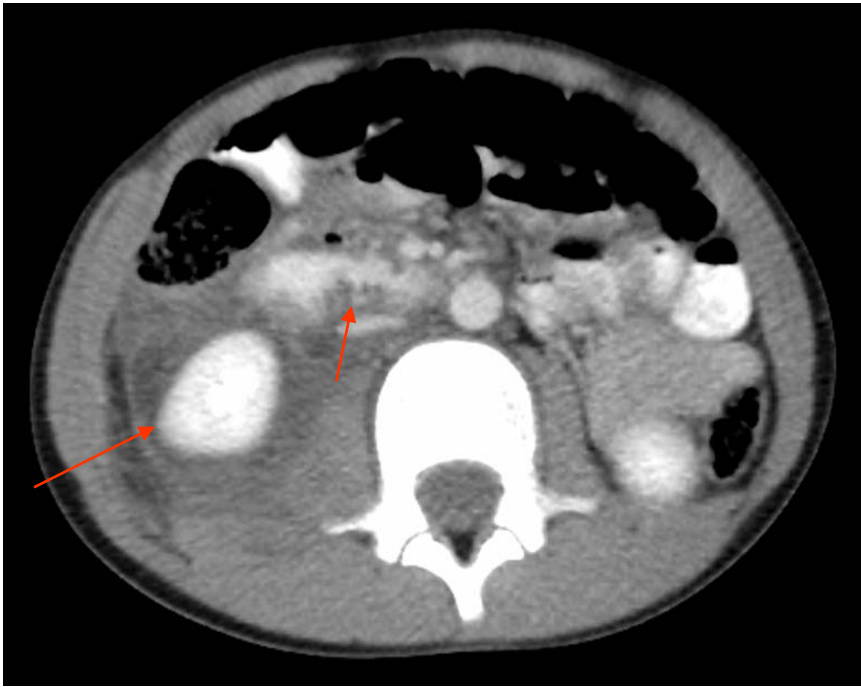Labs

- WBC 17.2 Hb 137
- U/A neg

CT: duodenal perforation junction D2/D3,
intra/retroperitoneal FF, retroperitoneal FA



Our Experience: SP



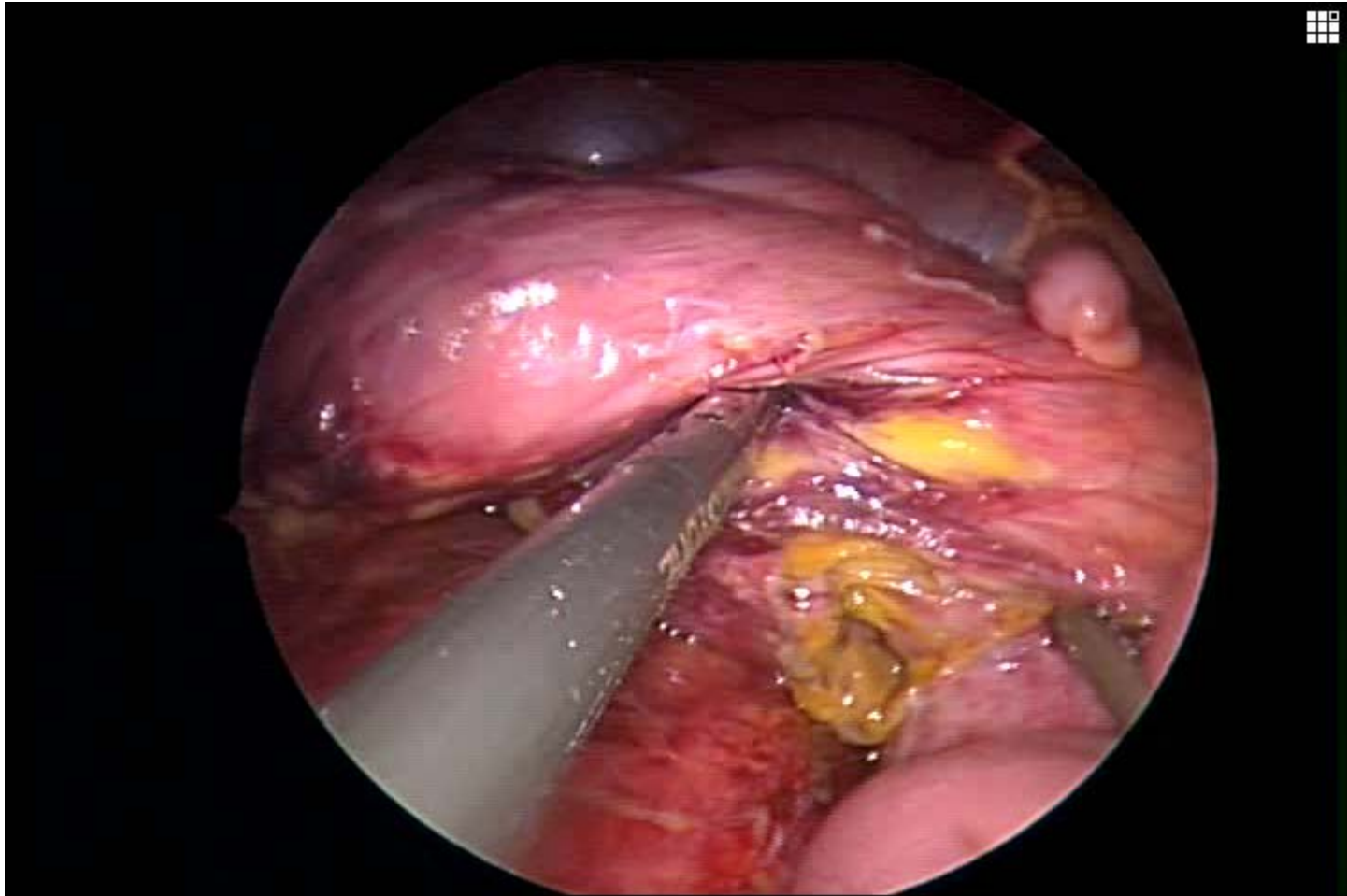
Our Experience: SP

laparoscopy

- cloudy pelvic + R paracolic FF, Ø blood, Ø gross enteric content
- mobilized R colon + D → bubbles + bilious fluid in plane b/w R kidney + D
- mobilized D to midline → ?D3 perf w/ bilious fluid but mucosa not seen, D otherwise healthy
- dissected posterior to R kidney → more bilious fluid

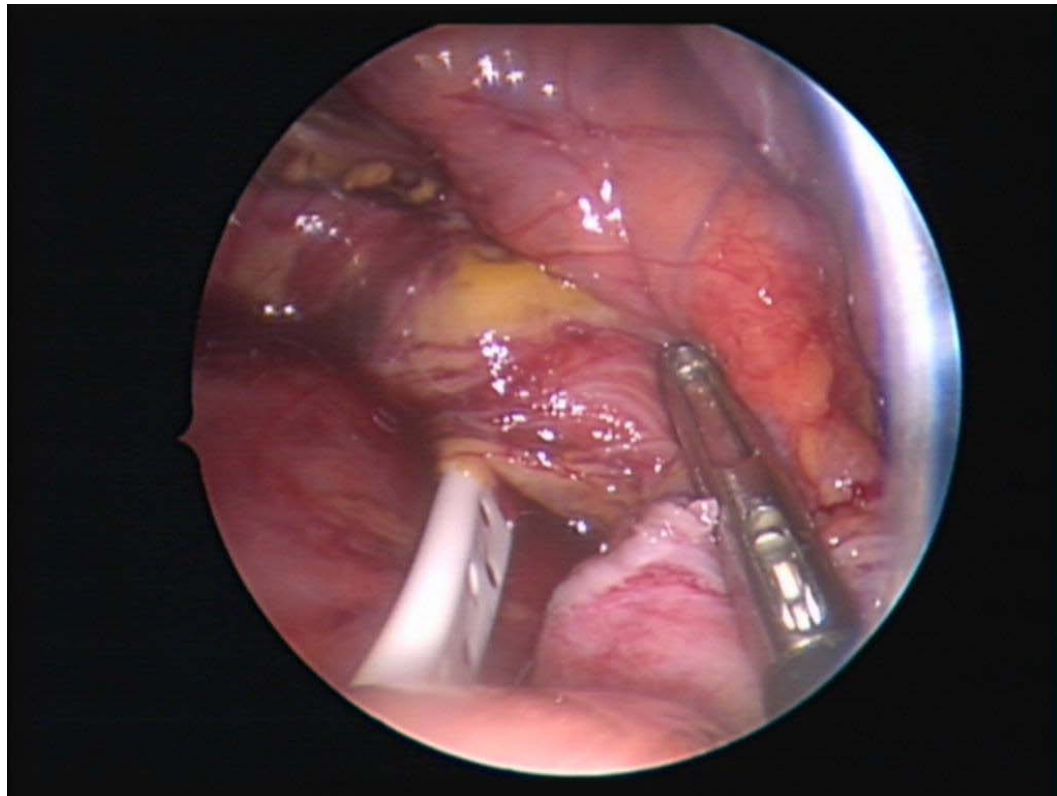


Our Experience: SP



Our Experience: SP

- » drained posterior to R kidney
- » drained into area of perforation



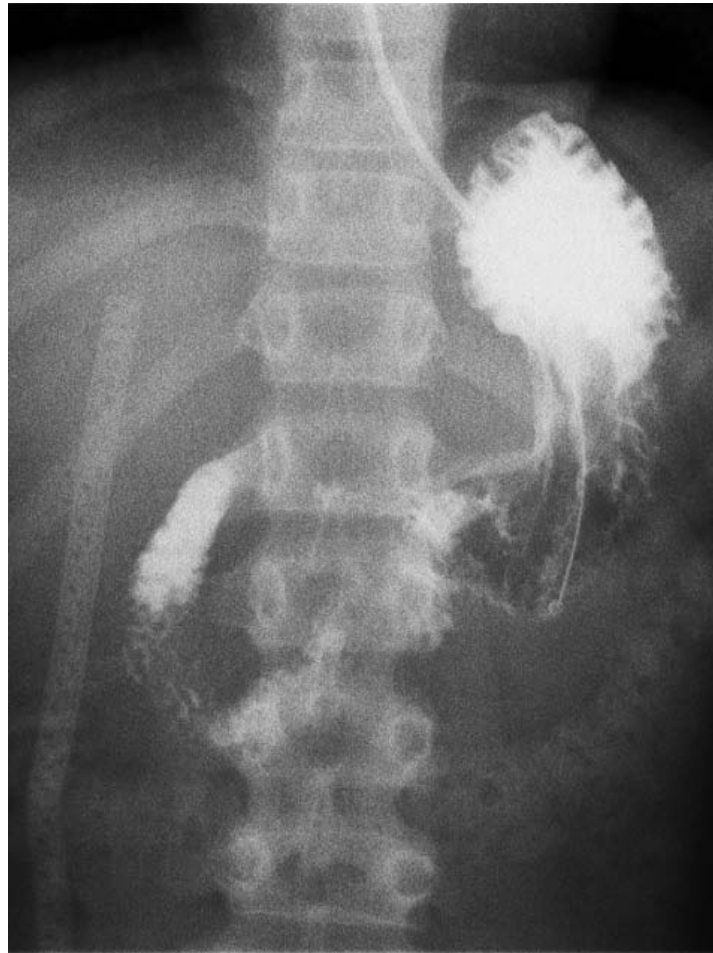Our Experience: SP

post-op

- NPO, NG, TPN
- ranitidine
- UGI POD#9: no leak → NG D/Cd + advanced po
→ JPs D/Cd
- home POD#13



Our Experience: SP



Conclusions and Proposed Algorithms

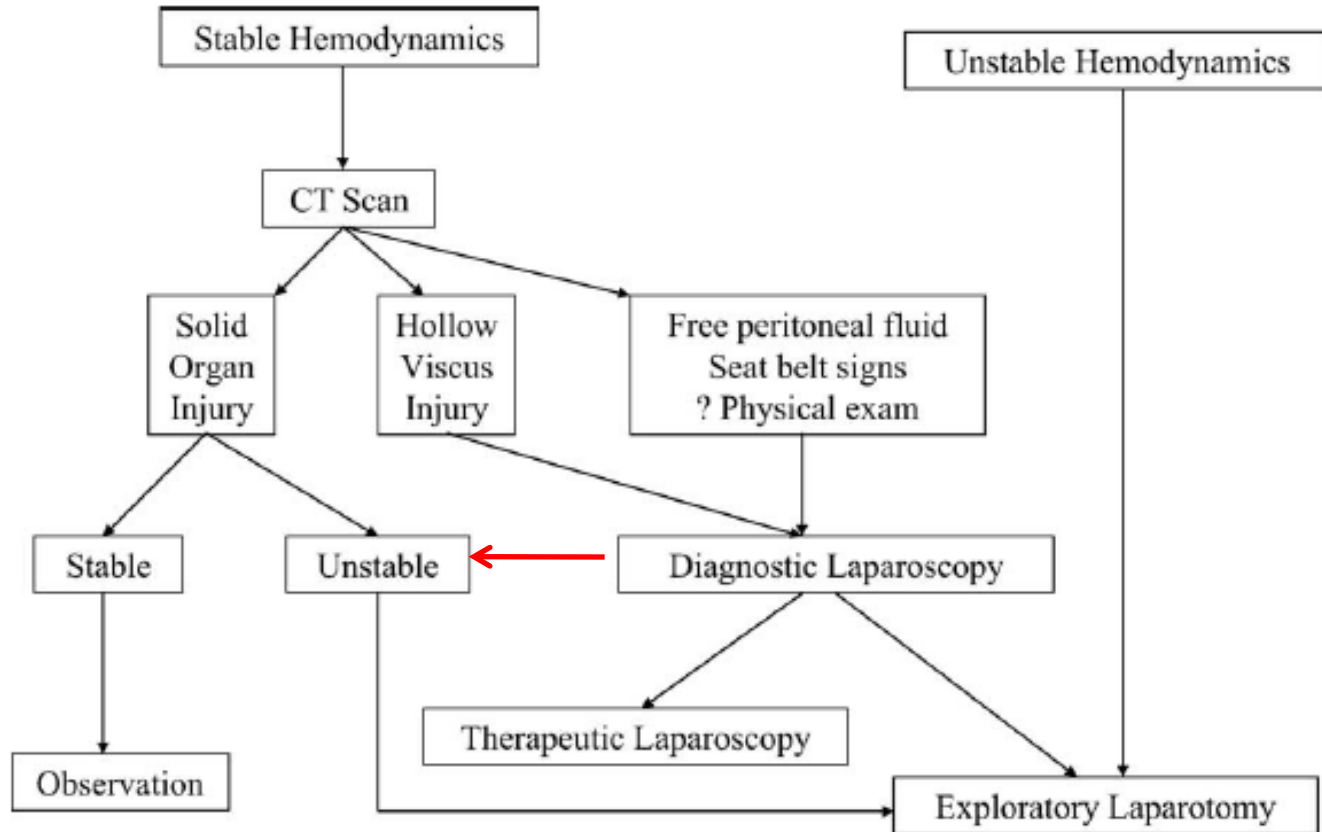


Fig. 1 Algorithm for laparoscopy in blunt abdominal trauma.



Conclusions and Proposed Algorithms

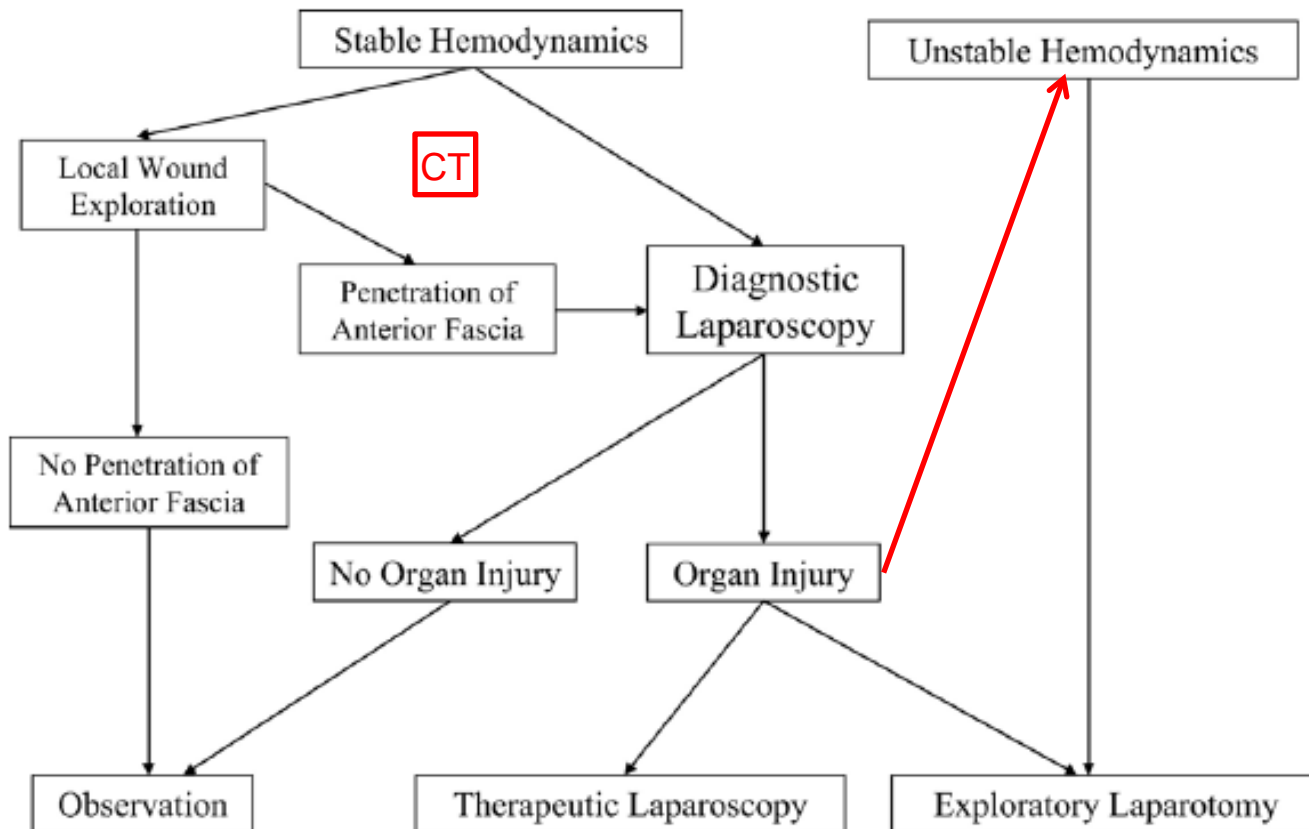


Fig. 2 Algorithm for laparoscopy in penetrating abdominal trauma (abdominal stab or tangential GSWs).



Thank you

Questions?

